ScienceDirect

Current Problems in Surgery
Available online 11 February 2026, 102003
In Press, Journal Pre-proof What's this?

Surgical Pain Control for Rib Fractures: Procedural Options for Acute and Persistent Pain

Vladislav Muldiiarov MD, Zachary M. Bauman DO, MHA, FACOS, FACS

Show more

Outline | Share Cite

https://doi.org/10.1016/j.cpsurg.2026.102003
Get rights and content

Under a Creative Commons license Open access

Abstract

Rib fractures are among the most common injuries after blunt thoracic trauma and can cause severe pain and chest wall dysfunction, limiting ventilation, cough, and mobilization and increasing the risk of pulmonary complications. Although surgical stabilization of rib fractures (SSRF) can improve mechanics and pain in selected patients, many patients require additional procedural strategies, either as adjuncts to SSRF or as stand-alone options when fixation is not indicated or feasible. This review summarizes key operative and procedure-based approaches to rib fracture analgesia, including elastomeric infusion pumps and continuous intercostal catheter techniques, intercostal radiofrequency ablation, intercostal cryoneurolysis, intercostal neurectomy, and peripheral nerve stimulation. For each modality, we highlight device or technique evolution, proposed mechanisms, typical clinical scenarios and timing (acute versus persistent neuropathic pain), available evidence on effectiveness, and the most relevant complications and safety considerations. The goal is to provide a practical framework to help clinicians match interventions to patient factors, injury pattern, contraindications to regional anesthesia, and the expected duration and phenotype of pain, while supporting respiratory recovery and functional outcomes.

Key Words

Rib fractures; Pain control; Radiofrequency ablation; Cryoneurolysis; peripheral nerve stimulator; Intercostal nerve; Neurectomy

Introduction

Pain control in patients with rib fractures is a crucial aspect of treatment, necessary to prevent secondary complications such as pneumonia, respiratory failure, prolonged mechanical ventilation, and opioid dependence, while also helping these patients cough, deep breathe, and carry out activities of daily living (ADLs)[1,2]. Effective pain management enhances patient comfort, improves respiratory function, and accelerates recovery, allowing patients to return to baseline functionality as quickly as possible[3,4]. Multimodal pain regimens have been mostly described in the literature for patients with rib fractures and their advantages over single agent use[5]. This often includes several oral and intravenous medications (acetaminophen, NSAIDs, muscle relaxants, medications specifically focused on nerve pain, opioids, and topicals)5, 6, 7, 8. Furthermore, local regional analgesia is commonly employed including epidural, serratus anterior muscle, erector spinae, paravertebral blocks, and individual intercostal nerve blocks (Figure 1)9, 10, 11, 12, 13, 14, 15. Although these bedside procedures carry risks such as pneumothorax and local anesthetic toxicity, these risks can be minimized through proper technique and strict monitoring of drug dosages[16].

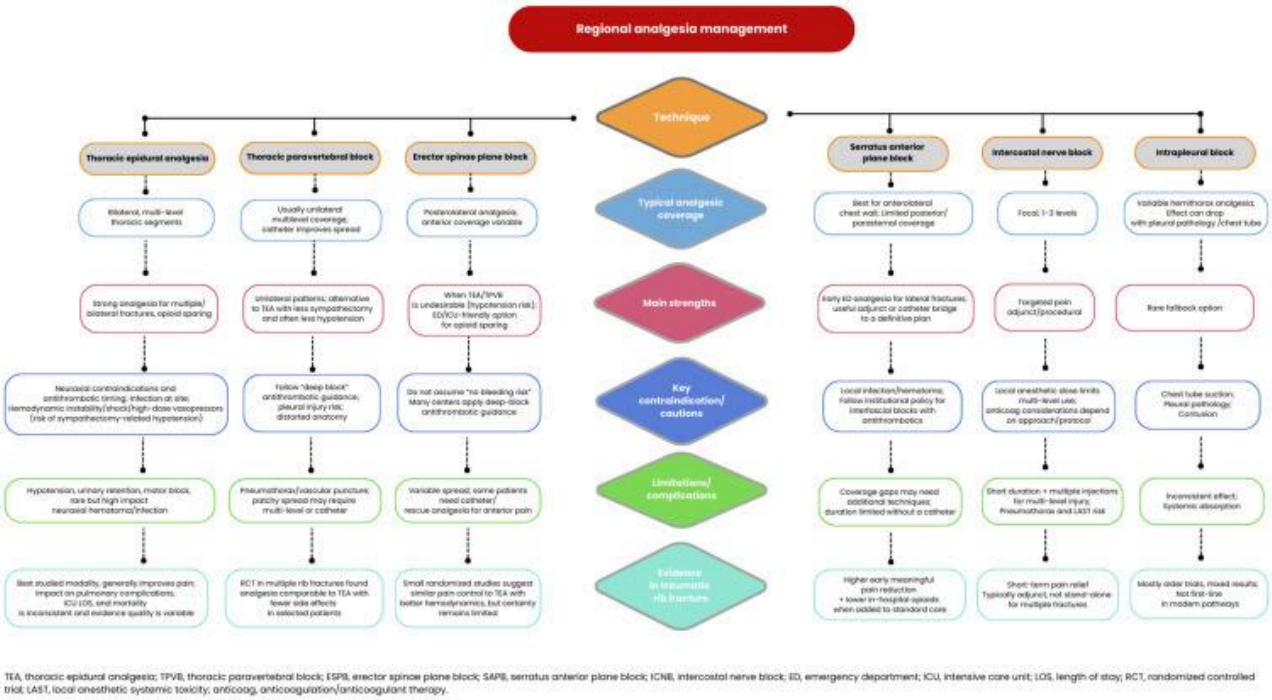

TEA, thoracic epidural analgesia; TPVB, thoracic paravertebral block; ESPB, erector spinae plane block; SAPB, serratus anterior plane block; ICNB, intercostal nerve block; ED, emergency department; ICU, intensive care unit; LOS, length of stay; RCT, randomized controlled trial; LAST, local anesthetic systemic toxicity; anticoag, anticoagulation/anticoagulant therapy.

Download: Download high-res image (695KB)

Download: Download full-size image

Figure 1. TEA, thoracic epidural analgesia; TPVB, thoracic paravertebral block; ESPB, erector spinae plane block; SAPB, serratus anterior plane block; ICNB, intercostal nerve block; ED, emergency department; ICU, intensive care unit; LOS, length of stay; RCT, randomized controlled trial: LAST; local anesthetic svstemic toxicitv: anticoag; anticoagulation/anticoagulant therapy.

It is also very important to accurately assess a patient's pain resulting from rib fractures. Pain from rib fractures is often underappreciated, especially in the hospital setting. A recent study by Bauman et al. demonstrated the pain from rib fractures is significantly less when a patient is lying in bed, still and not moving[17]. However, this pain significantly increases when a patient gets out of bed and starts going through a series of movements needed for that patient to perform their ADLs despite these patients often being on a multimodal pain regimen[17]. This is problematic as pain is often assessed by healthcare providers when a patient is lying in bed, but unfortunately this is not practical when looking at patient's desire to return to their

normal life. It is also important to remember patients cannot be discharged with local regional analgesia pain block catheters in place or on intravenous pain medications.

Over the past half-century, surgical methods for pain management have evolved significantly. In recent years, thoracic surgery has increasingly incorporated advanced techniques such as intercostal nerve cryoablation and nerve stimulators offering enhanced options for long-term chest wall pain control[18]. As the surgical stabilization of the rib fractures (SSRF) has gained popularity over the past two decades for the management of rib fractures, so too has the advent of surgical techniques for rib fracture pain control evolved. This review will briefly explore the development of the main procedural and surgical methods for pain management in rib fractures and discuss their current role and application in modern trauma care (Figure 2).

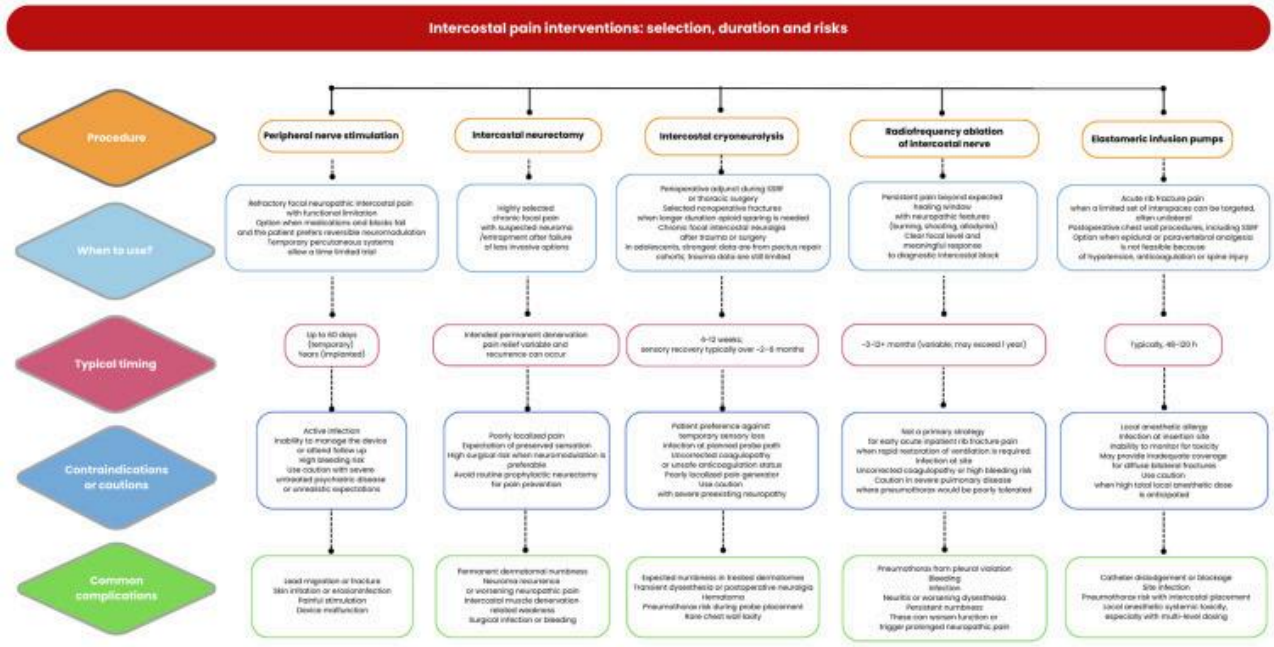

Download: Download high-res image (713KB)

Download: Download full-size image

Figure 2. should read as follows: "Breakdown of procedural intercostal nerve pain interventions: when to use; typical timing; contraindications or cautions; common complications.

Elastomeric infusion pumps

Irrigating surgical wounds with local anesthetic solutions originated from studies conducted in the early 1900s by Ewald Füllde and Walter Capelle, who developed the first system of continuous wound infiltration[19]. In the 1950s, this technique was refined for thoracotomy incisions by introducing thin catheters before wound closure, resulting in a notable reduction in opioid requirements[20]. However, the method did not gain widespread popularity until about 20 years later, when studies demonstrated its effectiveness in pain management for abdominal surgery[21,22]. Today, continuous wound infiltration is an actively used and popular method across various surgical specialties.

Elastomeric infusion pumps are small, portable, non-electronic disposable devices for continuous drug delivery. The duration of therapy typically ranges from 2 to 7 days, depending on the pump size[23,24]. These balloon-shaped pumps feature a soft, round exterior with a rigid cylindrical core that becomes more prominent when the pump delivers medication for more than 24 hours[24]. The elastomeric pump is connected

to a catheter with one or two lumens placed in or near the targeted area, for example, tunneled along fractured ribs or embedded within the surgical field[25]. The device delivers a local anesthetic to the designated area adjacent to relevant nerves, helping to reduce pain. Several types of elastomeric pumps are available: fixed flow rate, selectable flow rate, and patient-controlled demand dose[26]. Ropivacaine and bupivacaine are commonly used in these delivery systems for local anesthesia[27].

In thoracic surgery, elastomeric wound and chest wall infusion systems, including the ON-Q PainBuster platform, are commonly used to deliver continuous local anesthetic via subpleural or extrapleural catheters placed adjacent to the intercostal spaces and incision sites[28,29]. When the catheter is placed under direct visualization in the subpleural or extrapleural plane, pleural violation can be avoided and catheter position can be confirmed at the time of surgery[28]. Across elective thoracic procedures, randomized trials and prospective comparative studies suggest that continuous intercostal or extrapleural infusion can provide analgesia that is comparable to thoracic epidural analgesia in selected patients, with similar pulmonary function endpoints and, in some cohorts, reduced opioid exposure29, 30, 31.

In chest trauma, continuous intercostal nerve blockade using a tunneled catheter connected to an elastomeric reservoir has been reported as an effective adjunct for patients with multiple rib fractures, with improvements in pain control and pulmonary outcomes compared with conventional systemic regimens, and in some studies comparable or favorable pulmonary complication profiles versus epidural-based strategies32, 33, 34. In practice, these catheters may be inserted at the bedside for nonoperative rib fracture management, often with ultrasound guidance, or placed in the operating room during SSRF or thoracoscopy, where tunneling and secure fixation can be performed under controlled conditions[33].

Device performance and safety should be presented alongside efficacy. Bench and clinical evaluations show that elastomeric pump flow may deviate from the nominal rate under real-world conditions, particularly with changes in temperature, reservoir height relative to the catheter, and downstream resistance or back pressure[25]. Because these devices are passive and lack alarms, they require regular checks for premature reservoir emptying, failure to infuse, and line occlusion, and reported adverse events include leakage, dislodgement, occlusion (including in continuous wound infiltration systems), infection, and rare cases of clinically significant over infusion35, 36, 37. In chest wall applications, pneumothorax remains a procedure-specific risk, and higher-dose truncal infusions carry a small but serious risk of local anesthetic systemic toxicity, underscoring the need for conservative dosing, monitoring, and preparedness to implement the ASRA LAST checklist[16].

Radiofrequency ablation

Radiofrequency ablation (RFA) utilizes radiofrequency energy to generate heat and induce tissue necrosis. In this minimally invasive procedure, radio waves ranging from 100 to 500 kHz are applied near the target nerve to alter its nociceptive pathways, thereby reducing the patient's pain38, 39, 40. The first known application of RFA was the thermocoagulation of the Gasserian ganglion. In the early 1930s, Kirschner demonstrated that continuous radiofrequency currently creates focal thermal lesions in neural pathways to interrupt nociception[38]. By the 1950s, work by Cosman led to the advent of the first commercially available radiofrequency (RF) systems and the initial use of RF in pain treatment occurred in 1974 when continuous radiofrequency was employed to deliver thermal energy through a percutaneous probe with an electrode tip

to ablate a nerve[39]. Subsequently, Bogduk refined percutaneous medial branch RF neurotomy techniques, effectively replacing surgical neurotomy[40].

Prolonged exposure to high temperatures in continuous radiofrequency (CRF) causes cellular and acellular structures coagulative necrosis. Histologically, this results in axonal degeneration and destruction of collagen fibers within the endoneurial, perineurial, and epineurial structures[41]. Due to the extended duration of functional loss and nerve damage, CRF induces third- or fourth-degree injuries corresponding to Wallerian degeneration and is associated with the potential for neuroma formation[41]. Functional, albeit incomplete, reinnervation of the area typically occurs over a period ranging from months to a year[41].

Water-cooled radiofrequency ablation is an alternative RF technique in which a continuously cooled electrode limits overheating at the probe–tissue interface, allowing larger and more consistent thermal lesions[42]. Cooling reduces tissue charring and coagulum formation, helps avoid impedance rise, and keeps the electrode tract functional during lesion creation[42]. This can be helpful when the pain generator has multiple or variable innervation targets. The procedure delivers catheter-controlled RF current through an electrode positioned near the nociceptive pathway, typically under fluoroscopic guidance[42]. In conventional RF, once the target temperature is reached, energy is cycled to maintain the set point, and clinically relevant neural injury begins as tissue temperatures exceed roughly 45°C[43].

Pulsed radiofrequency (PRF) is commonly described as a less neurodestructive alternative to continuous RF. Standard PRF protocols deliver a 500-kHz current in brief bursts (typically 2 Hz with a 20-ms pulse width), which keeps target temperatures below neuroablative levels and shifts the dominant effect toward a high-intensity electric field concentrated at the electrode tip (reported up to ~185,000 V/m)[44]. This field can modulate neural function through non-thermal mechanisms, including effects on transmembrane potentials and ion channel behavior, and experimental work has demonstrated reversible ultrastructural changes after PRF exposure, such as abnormal mitochondrial morphology and disorganization of microtubules and microfilaments[44,45]. Clinically, the tradeoff is durability: in comparative trials, pain and functional improvement after PRF may attenuate earlier than after CRF, which can lead to more frequent repeat procedures in some patient groups[46].

Recently, RFA has gained popularity for utilization on intercostal nerves for patients with rib fractures and intercostal neuralgia. It is often reserved for patients with ongoing chronic pain from their rib fractures. Although this therapy can be completed surgically, it is often performed utilizing fluoroscopic guidance with a 17-gauge needle and electrode placed at inferior border of the rib near the intercostal nerve. Each intercostal nerve radiofrequency ablation is performed for approximately 2 minutes with a target temperature of 80°C around the electrode. Although adverse effects from thermal lesioning are exceedingly rare, potential complications include bleeding, infection, nerve injury from needle insertion, burns due to improper grounding pad placement, and transient post-procedural discomfort[47]. For rib fracture and blunt chest trauma pain, the evidence for intercostal RFA is still limited to case reports and small series that suggest meaningful pain relief and, in some patients, improved inspiratory performance[47, 48, 49]. Larger prospective studies are needed to define durability, optimal patient selection, and long-term outcomes.

Intercostal Nerve Cryoablation

Cryoablation of nerves is a technique involving the controlled freezing of nerves to achieve prolonged analgesia. Since its inception, this method has significantly evolved. In 1961, Cooper and colleagues developed

one of the first cryoprobes capable of reaching temperatures as low as -190 °C using liquid nitrogen[50]. In 1969, the ophthalmic surgeon Amoils enhanced the technology by utilizing carbon dioxide and nitrous oxide to create a cryoprobe that could reach temperatures of -70 °C[51]. Building on these advancements, Nelson and co-authors first described intraoperative intercostal cryoneurolysis in 38 patients in 1974. The results demonstrated that patients who underwent cryoneurolysis showed a significant reduction in postoperative opioid use compared to the control group (661.0 mg vs. 855.2 mg of meperidine, $p < 0.05$)[52].

However, despite these promising results and widespread use of the method, interest in intercostal cryoneurolysis among thoracic surgeons declined significantly by the mid-1990s. This decline was due to conflicting data on its efficacy, the proliferation of thoracic epidural catheters, and reports of potentially significant neuralgia.

Understanding the mechanisms of action of cryoneurolysis is critical to assessing its effectiveness and safety. Exposure to temperatures in the approximate range of −40°C to −100°C is intended to produce a Sunderland grade II injury (controlled axonotmesis) with distal Wallerian degeneration while preserving the endoneurium, perineurium, and epineurium; temperatures colder than −100°C are associated with stromal disruption and a higher risk of irreversible nerve injury[53]. Because the endoneurium, perineurium, and epineurium remain intact, axons can regenerate along performed pathways, and recovery is therefore predictable and length dependent, typically on the order of about 1–2 mm per day in clinical discussions of cryoneurolysis and about 1 mm per day in broader peripheral nerve regeneration literature[54].

Analgesia lasts until reinnervation restores conduction, which most commonly translates to weeks to months, depending on nerve diameter and the distance from the ablation site to the terminal field[54]. In contrast, partial or inadequate freezing may fail to provide analgesia and can provoke a painful neurapraxia, emphasizing the need for complete circumferential capture of the target nerve within the ice ball. Technical factors materially influence outcomes. Cryoneurolysis probes generate low temperatures at the tip by expanding a high-pressure gas, most commonly nitrous oxide or carbon dioxide, within a closed-ended probe; rapid expansion produces cooling via the Joule–Thomson effect and forms an “ice ball” that envelops the nerve[55]. The ice ball creates a conduction block through axonal degeneration distal to the freeze zone while maintaining the external nerve architecture needed for regeneration[55].

Recent device refinements and a clearer understanding of reversible axonotmesis have renewed interest in intercostal nerve cryoneurolysis for chest wall pain, including rib fractures. In operative trauma care, cryoneurolysis can be performed at the time of SSRF or during other thoracic procedures, using either an intrathoracic or extrathoracic exposure to identify the intercostal nerve and deliver a controlled freeze at each treated level. Typical surgical protocols apply cryo at approximately −60 to −70°C for about 2 minutes per level, with careful attention to treatment location and spacing[56]. It is important to note that intercostal nerve cryoablation must occur at a minimum of 4 cm from the thoracic spine and it is recommended by the Food and Drug Administration to only cryoablate intercostal nerve 3 – 9 to avoid additional complications[57].

In patients with traumatic rib fractures, growing clinical literature supports cryoneurolysis as an effective adjunct to multimodal analgesia. Multi-institutional and single-center retrospective studies of SSRF plus intercostal cryoablation have reported lower postoperative opioid requirements and shorter ICU or ventilator durations without an apparent increase in perioperative pulmonary complications[18,58, 59]. Direct technique comparisons also suggest that intrathoracic SSRF approaches combined with cryoablation may further reduce postoperative opioid consumption compared with extrathoracic plating in otherwise similar cohorts[60].

Beyond the operating room, ultrasound-guided percutaneous cryoneurolysis has expanded access for nonoperative patients, with small series demonstrating improved pain scores and, in some patients, improved incentive spirometry after bedside treatment[61,62]. For broader context across thoracic surgery and trauma-related chest wall pain, a dedicated systematic review found analgesic benefit across heterogeneous studies while emphasizing variable protocols and the need for higher-quality comparative trials[63].

Reported adverse events are usually mild and self-limited, including local bruising, swelling, and transient sensory changes, but longer-term neuropathic symptoms and allodynia have been reported after thoracotomy cryoanalgesia in comparative studies[64,65]. For rib fracture populations, the evidence base still consists predominantly of retrospective cohorts and small percutaneous series, so conclusions about long-term outcomes, optimal level selection, and comparative effectiveness versus other regional techniques remain limited61, 62, 63. Practical risk mitigation includes strict adherence to device-specific anatomic recommendations, avoidance of very caudal interspaces, and careful technique to minimize pleural injury and pneumothorax risk when working near the intercostal space[60].

Persistent pain and intercostal neuralgia after rib fractures

Persistent pain after rib fractures is common and can meaningfully limit recovery. In a prospective cohort, nearly 40% of patients managed non-operatively reported some degree of rib pain at 1 year, with persistent impairment in physical recovery domains[66]. When pain persists beyond the expected healing window and has neuropathic features, including burning or shooting quality, dermatomal radiation, hyperalgesia or allodynia, and focal tenderness or Tinel sign near a fracture site or callus, post-traumatic intercostal neuralgia should be considered[67]. Objective support may include imaging evidence of malunion or exuberant callus near the neurovascular bundle, and a positive diagnostic intercostal nerve block with meaningful temporary relief[67].

Management is best structured as a stepwise multimodal pathway. Initial therapy includes non-opioid analgesics, neuropathic agents when appropriate, pulmonary hygiene, and directed physical therapy. For focal neuropathic pain refractory to conservative care, targeted interventional options may be considered. Ultrasound-guided percutaneous cryoneurolysis has recently been evaluated in traumatic rib fracture pain in a randomized, active-controlled, participant- and observer-masked trial, supporting its role as an escalation option in selected patients[61]. Radiofrequency ablation has also been reported for resistant intercostal neuralgia, although the current evidence base is limited and largely consists of small series and case reports[68].

For patients with suspected neuroma or nerve entrapment related to rib fracture healing, surgical options may be appropriate after failure of less invasive measures. Neurectomy, typically combined with management of the nerve stump to reduce recurrent neuroma symptoms, may be considered as a salvage approach when pain remains clearly localized and corroborated by exam, imaging, and diagnostic blocks[69]. Potential complications after intercostal neurectomy include persistent numbness in the involved dermatome, recurrent neuroma pain, and incomplete or transient symptom relief, emphasizing the need for careful patient selection and counseling[69].

Neuromodulation is another option for carefully selected patients. Peripheral nerve stimulation (PNS) is conceptually grounded in the Gate Control Theory[70] and is increasingly used for focal neuropathic pain syndromes. Ultrasound-guided techniques for intercostal PNS lead placement have been described, and contemporary reports demonstrate meaningful and durable symptom reduction in refractory intercostal neuralgia, including after traumatic injury[71,72]. Consensus guidelines emphasize appropriate screening and

typically recommend proceeding after a positive diagnostic block or stimulation trial[73]. Common complications include infection, bleeding or hematoma, lead migration, lead fracture, and device malfunction, and these risks should be weighed against expected functional benefit and the patient's ability to adhere to follow-up[73]. Overall, persistent intercostal pain after rib fractures is best addressed with a comprehensive multimodal strategy tailored to the patient's pain phenotype, function, and goals.

Practical multimodal plans by pain phase and associated injuries

Figure 2 summarizes the key analgesic options discussed in this review, including typical timing, selection factors, contraindications, and complications. This section provides practical multimodal plans that clarify when each approach is most appropriate, organized by pain phase, with brief modifiers for common concurrent injuries and age-related considerations.

Acute phase (first 72 hours). The priority is to restore ventilation, cough, and early mobilization while limiting opioid related hypoventilation and delirium. It is recommended to use a scheduled non-opioid foundation and reassess pain during movement and respiratory therapy, not only at rest. Escalate early to regional or catheter-based options when pain limits breathing or mobility, especially in patients with high pulmonary risk. If neuraxial or paravertebral techniques are constrained by anticoagulation, hypotension, or monitoring needs, consider alternative regional strategies or continuous local anesthetic delivery tailored to unilateral or focal fracture patterns. Maintain conservative local anesthetic dosing and structured monitoring.

Early recovery phase (after 72 hours through early healing). The goals shift to maintaining daytime function, improving sleep, enabling rehabilitation, and tapering opioids. Continue the non-opioid base and transition to the least invasive regimen that preserves function. Procedural choices should match the expected duration of clinically limiting pain and the discharge plan. For operative patients, consider longer duration opioid sparing strategies as perioperative adjuncts when appropriate. For adolescents, procedural escalation should be individualized with counseling about expected duration, sensory changes, and limited trauma specific evidence for some modalities.

In older adults, and in patients with COPD or limited pulmonary reserve, an opioid sparing plan with early regional analgesia is often the best starting point. This helps reduce atelectasis, delirium, and prolonged immobility. When spinal cord injury is present, if the patient is hemodynamically unstable or serial neurologic exams are needed, favor techniques that do not worsen hypotension or complicate monitoring. The chosen approach should also fit spine precautions and the practical constraints of ICU care. For patients on anticoagulation or with coagulopathy, postpone higher bleeding risk procedures until anticoagulation can be optimized in coordination with the treating teams. In the meantime, use lower risk options when feasible.

Limitations

This review is narrative in design and was intended to provide a practical overview rather than a formal systematic review. As a result, study selection and weighting of evidence may be influenced by publication availability and author judgment. The literature on procedural and surgical rib fracture analgesia is also highly heterogeneous. Across studies, patient populations vary by age, comorbidity burden, injury severity, and the presence of associated traumatic injuries or patient comorbidities. Interventions differ in technique, device type, target levels, operator experience, and perioperative or inpatient care pathways. Outcomes are reported inconsistently, with variable definitions and timepoints for pain scores, opioid consumption, pulmonary

complications, mobility, and length of stay. These factors limit direct comparisons between modalities and make it difficult to identify a single optimal strategy.

For several interventions, the evidence base is limited by observational designs, small cohorts, and selection bias. Patients offered advanced analgesic procedures are often those with more severe injuries or with contraindications to standard regional techniques, which can confound comparisons. In addition, adverse events may be underreported, especially in small series, and follow-up is often short, which restricts conclusions about durability, late complications, and the transition from acute nociceptive pain to chronic neuropathic pain. Finally, there remains a shortage of head-to-head comparative studies and well powered randomized trials that evaluate clinically meaningful endpoints using standardized protocols.

Conclusion

When nonoperative measures are insufficient, elastomeric infusion pumps, radiofrequency ablation, cryoneurolysis, neurectomy, and peripheral nerve stimulation can improve rib fracture pain and function. These options are generally safe, but clinicians should counsel patients on key risks, including catheter issues or infection, pneumothorax or bleeding, sensory change, and device-related complications. Furthermore, these procedures can accompany SSRF or be used independently, something that also needs to be considered on an individual patient basis. The best results come from a multimodal plan that pairs a targeted procedure with medications and physiotherapy based on the patient's pain pattern and clinical constraints.

Special issue articles Recommended articles

References

1 V. Thiruvenkatarajan, H. Cruz Eng, S.D. Adhikary
An update on regional analgesia for rib fractures
Curr Opin Anaesthesiol, 31 (5) (2018), pp. 601-607
Crossref ↗ View in Scopus ↗ Google Scholar ↗

2 S.S. Koushik, A. Bui, K. Slinchenkova, *et al.*
Analgesic Techniques for Rib Fractures-A Comprehensive Review Article
Curr Pain Headache Rep, 27 (11) (2023), pp. 747-755, 10.1007/s11916-023-01172-9 ↗
View in Scopus ↗ Google Scholar ↗

3 Y. Yang, J.B. Young, C.R. Schermer, GH. Utter
Use of ketorolac is associated with decreased pneumonia following rib fractures
Am J Surg, 207 (4) (2014), pp. 566-572, 10.1016/j.amjsurg.2013.05.011 ↗
View PDF View article View in Scopus ↗ Google Scholar ↗

4 E.M. Bulger, T. Edwards, P. Klotz, GJ. Jurkovich
Epidural analgesia improves outcome after multiple rib fractures
Surgery, 136 (2) (2004), pp. 426-430, 10.1016/j.surg.2004.05.019 ↗
View PDF View article View in Scopus ↗ Google Scholar ↗

5 J.A. Harvin, R. Albarado, V.T.T. Truong, *et al.*

Multi-Modal Analgesic Strategy for Trauma: A Pragmatic Randomized Clinical Trial
J Am Coll Surg, 232 (3) (2021), pp. 241-251, 10.1016/j.jamcollsurg.2020.12.014 ↗
e3
View in Scopus ↗ Google Scholar ↗

6 S.W. Burton, C. Riojas, G. Gesin, *et al.*
Multimodal analgesia reduces opioid requirements in trauma patients with rib fractures
J Trauma Acute Care Surg, 92 (3) (2022), pp. 588-596, 10.1097/TA.0000000000003486 ↗
View in Scopus ↗ Google Scholar ↗

7 L.P. Deloney, M. Smith Condeni, C. Carter, A. Privette, S. Leon, E.A. Eriksson
Efficacy of Methocarbamol for Acute Pain Management in Young Adults With Traumatic Rib Fractures
Ann Pharmacother, 55 (6) (2021), pp. 705-710, 10.1177/1060028020964796 ↗
View in Scopus ↗ Google Scholar ↗

8 E.E. Moskowitz, L. Garabedian, K. Hardin, *et al.*
A double-blind, randomized controlled trial of gabapentin vs. placebo for acute pain management in critically ill patients with rib fractures
Injury, 49 (9) (2018), pp. 1693-1698, 10.1016/j.injury.2018.06.002 ↗
View PDF View article View in Scopus ↗ Google Scholar ↗

9 M.R. Moon, F.A. Luchette, S.W. Gibson, *et al.*
Prospective, randomized comparison of epidural versus parenteral opioid analgesia in thoracic trauma
Ann Surg, 229 (5) (1999), pp. 684-692, 10.1097/00000658-199905000-00011 ↗
View in Scopus ↗ Google Scholar ↗

10 G. Yeying, Y. Liyong, C. Yuebo, *et al.*
Thoracic paravertebral block versus intravenous patient-controlled analgesia for pain treatment in patients with multiple rib fractures
J Int Med Res, 45 (6) (2017), pp. 2085-2091, 10.1177/0300060517710068 ↗
View in Scopus ↗ Google Scholar ↗

11 S. Ramesh, S.M. Ayyan, D.P. Rath, DM. Sadanandan
Efficacy and safety of ultrasound-guided erector spinae plane block compared to sham procedure in adult patients with rib fractures presenting to the emergency department: A randomized controlled trial
Acad Emerg Med, 31 (4) (2024), pp. 316-325, 10.1111/acem.14820 ↗
View in Scopus ↗ Google Scholar ↗

12 C. Partyka, S. Asha, M. Berry, *et al.*
Serratus Anterior Plane Blocks for Early Rib Fracture Pain Management: The SABRE Randomized Clinical Trial
JAMA Surg, 159 (7) (2024), pp. 810-817, 10.1001/jamasurg.2024.0969 ↗
View in Scopus ↗ Google Scholar ↗

13 Ş Tekşen, G. Öksüz, H. Öksüz, *et al.*
Analgesic efficacy of the serratus anterior plane block in rib fractures pain: A randomized controlled trial
Am J Emerg Med, 41 (2021), pp. 16-20, 10.1016/j.ajem.2020.12.041 ↗
View PDF View article View in Scopus ↗ Google Scholar ↗

14 S. Hashemzadeh, K. Hashemzadeh, H. Hosseinzadeh, R. Aligholipour Maleki, S.E. Golzari
Comparison thoracic epidural and intercostal block to improve ventilation parameters and reduce pain in patients with multiple rib fractures
J Cardiovasc Thorac Res, 3 (3) (2011), pp. 87-91, 10.5681/jcvtr.2011.019 ↗
Google Scholar ↗

15 S. Stopenski, J. Binkley, S.D. Schubl, ZM. Bauman
Rib fracture management: A review of surgical stabilization, regional analgesia, and intercostal nerve cryoablation
Surgery in Practice and Science, 10 (2022), Article 100089
View PDF View article View in Scopus ↗ Google Scholar ↗

16 J.M. Neal, E.J. Neal, GL. Weinberg
American Society of Regional Anesthesia and Pain Medicine Local Anesthetic Systemic Toxicity checklist: 2020 version
Reg Anesth Pain Med, 46 (1) (2021), pp. 81-82, 10.1136/rapm-2020-101986 ↗
View in Scopus ↗ Google Scholar ↗

17 Z.M. Bauman, J. Phillips, Y. Tian, L. Cavlovic, A. Raposo-Hadley, H. Khan, C.H. Evans, A. Kamien, S. Cemaj, O. Sheppard, G. Lamb, J. Veatch, M. Matos, E. Cantrell
It doesn't hurt as long as I don't move: Aligning pain assessment in patients with rib fractures with mobilization needed for recovery
J *Trauma Acute Care Surg* (2024 Oct 15), 10.1097/TA.0000000000004446 ↗
Google Scholar ↗

18 Z.M. Bauman, J. Loftus, A. Raposo-Hadley, *et al.*
Surgical stabilization of rib fractures combined with intercostal nerve cryoablation proves to be more cost effective by reducing hospital length of stay and narcotics
Injury, 52 (5) (2021), pp. 1128-1132
View PDF View article View in Scopus ↗ Google Scholar ↗

19 W. Capelle, E. Fulde
Die postoperativen Störungen der Atemmechanik und ihre Rückwirkungen auf die Lungen
Dtsch Z Chir, 240 (1933), pp. 673-680
View in Scopus ↗ Google Scholar ↗

20 B. Blades, WB. Ford
A method for control of postoperative pain
Surg Gynecol Obstet, 91 (5) (1950), pp. 524-526
View in Scopus ↗ Google Scholar ↗

21 J.F. Chester, K. Ravindranath, B.D. White, D. Shanahan, R.S. Taylor, K. Lloyd-Williams
Wound perfusion with bupivacaine: objective evidence for efficacy in postoperative pain relief
Ann R Coll Surg Engl, 71 (6) (1989), pp. 394-396
View in Scopus ↗ Google Scholar ↗

22 I.D. Levack, J.D. Holmes, GS. Robertson
Abdominal wound perfusion for the relief of postoperative pain
Br J Anaesth, 58 (6) (1986), pp. 615-619, 10.1093/bja/58.6.615 ↗
View PDF View article View in Scopus ↗ Google Scholar ↗

23 X. Capdevila, P. Pirat, S. Bringuier, *et al.*
Continuous peripheral nerve blocks in hospital wards after orthopedic surgery: a multicenter prospective analysis of the quality of postoperative analgesia and complications in 1,416 patients
Anesthesiology, 103 (5) (2005), pp. 1035-1045, 10.1097/00000542-200511000-00018 ↗
View in Scopus ↗ Google Scholar ↗

24 BM. Ilfeld
Continuous Peripheral Nerve Blocks: An Update of the Published Evidence and Comparison With Novel, Alternative Analgesic Modalities
Anesth Analg, 124 (1) (2017), pp. 308-335, 10.1213/ANE.0000000000001581 ↗
View in Scopus ↗ Google Scholar ↗

25 R.S. Weisman, A. Missair, P. Pham, J.F. Gutierrez, RE. Gebhard
Accuracy and consistency of modern elastomeric pumps
Reg Anesth Pain Med, 39 (5) (2014 Sep-Oct), pp. 423-428, 10.1097/AAP.0000000000000130 ↗
PMID: 25140510
View in Scopus ↗ Google Scholar ↗

26 F. Remerand, A.S. Vuitton, M. Palud, *et al.*
Elastomeric pump reliability in postoperative regional anesthesia: a survey of 430 consecutive devices
Anesth Analg, 107 (6) (2008), pp. 2079-2084, 10.1213/ane.0b013e318187c9bb ↗
View in Scopus ↗ Google Scholar ↗

27 M.S. Truitt, R.C. Mooty, J. Amos, M. Lorenzo, A. Mangram, E. Dunn
Out with the old, in with the new: a novel approach to treating pain associated with rib fractures
World J Surg, 34 (10) (2010), pp. 2359-2362, 10.1007/s00268-010-0651-9 ↗
View in Scopus ↗ Google Scholar ↗

28 FC. Detterbeck
Subpleural catheter placement for pain relief after thoracoscopic resection
Ann Thorac Surg, 81 (4) (2006), pp. 1522-1523, 10.1016/j.athoracsur.2005.01.057 ↗
View PDF View article View in Scopus ↗ Google Scholar ↗

29 M. Ried, C. Schilling, T. Potzger, *et al.*
Prospective, comparative study of the On-Q® PainBuster® postoperative pain relief system and thoracic epidural analgesia after thoracic surgery
J Cardiothorac Vasc Anesth, 28 (4) (2014), pp. 973-978, 10.1053/j.jvca.2013.12.028 ↗
View PDF View article View in Scopus ↗ Google Scholar ↗

30 G. Debreceni, Z. Molnár, L. Szélig, TF. Molnár
Continuous epidural or intercostal analgesia following thoracotomy: a prospective randomized double-blind clinical trial
Acta Anaesthesiol Scand, 47 (9) (2003), pp. 1091-1095, 10.1034/j.1399-6576.2003.00208.x ↗
View in Scopus ↗ Google Scholar ↗

31 J.D. Luketich, S.R. Land, E.A. Sullivan, *et al.*
Thoracic epidural versus intercostal nerve catheter plus patient-controlled analgesia: a randomized study
Ann Thorac Surg, 79 (6) (2005), pp. 1845-1850, 10.1016/j.athoracsur.2004.10.055 ↗
View PDF View article View in Scopus ↗ Google Scholar ↗

32 R. Uhlich, J.D. Kerby, P. Bosarge, P. Hu
Use of continuous intercostal nerve blockade is associated with improved outcomes in patients with multiple rib fractures
Trauma Surg Acute Care Open, 6 (1) (2021), Article e000600, 10.1136/tsaco-2020-000600 ↗
Published 2021 Apr 26
View in Scopus ↗ Google Scholar ↗

33 M.S. Truitt, J. Murry, J. Amos, *et al.*
Continuous intercostal nerve blockade for rib fractures: ready for primetime?
J Trauma, 71 (6) (2011), pp. 1548-1552, 10.1097/TA.0b013e31823c96e0 ↗
View in Scopus ↗ Google Scholar ↗

34 L.A. O'Connor, B. Houseman, T. Cook, CC. Quinn
Intercostal cryonerve block versus elastomeric infusion pump for postoperative analgesia following surgical stabilization of traumatic rib fractures
Injury, 54 (11) (2023), Article 111053, 10.1016/j.injury.2023.111053 ↗
View PDF View article View in Scopus ↗ Google Scholar ↗

35 B. Bungart, L. Joudeh, M. Fettiplace
Local anesthetic dosing and toxicity of adult truncal catheters: a narrative review of published practice
Reg Anesth Pain Med, 49 (3) (2024), pp. 209-222, 10.1136/rapm-2023-104667 ↗
Published 2024 Mar 4
Google Scholar ↗

36 K. Shimizu, T. Hoshi, T. Iijima
Occlusion of multi-holed catheters used in continuous wound infusion in open gynecologic surgery: A pathological study

Saudi J Anaesth, 14 (3) (2020), pp. 302-306, 10.4103/sja.SJA_709_19 ↗

View in Scopus ↗ Google Scholar ↗

37 G. Paladini, S. Di Carlo, G. Musella, *et al.*
Continuous Wound Infiltration of Local Anesthetics in Postoperative Pain Management: Safety, Efficacy and Current Perspectives
J Pain Res, 13 (2020), pp. 285-294, 10.2147/JPR.S211234 ↗
Published 2020 Jan 31

View in Scopus ↗ Google Scholar ↗

38 M. Krischner
Zur elektrochirurgie[For electrosurgery]
Arch Klin Chir, 147 (1931), p. 761
German

Google Scholar ↗

39 S. Uematsu, G.B. Udrarhelyi, D.W. Benson, *et al.*
Percutaneous radiofrequency rhizotomy
Surg Neurol, 2 (1974), pp. 319-325

View in Scopus ↗ Google Scholar ↗

40 N. Bogduk, DM. Long
The anatomy of the so-called “articular nerves” and their relationship to facet denervation in the treatment of low-back pain
J Neurosurg, 51 (2) (1979), pp. 172-177, 10.3171/jns.1979.51.2.0172 ↗

View in Scopus ↗ Google Scholar ↗

41 E.J. Choi, Y.M. Choi, E.J. Jang, J.Y. Kim, T.K. Kim, KH. Kim
Neural Ablation and Regeneration in Pain Practice
Korean J Pain, 29 (1) (2016), pp. 3-11, 10.3344/kjp.2016.29.1.3 ↗

View in Scopus ↗ Google Scholar ↗

42 F. Burdío, E.J. Berjano, A. Navarro, *et al.*
RF tumor ablation with internally cooled electrodes and saline infusion: what is the optimal location of the saline infusion?
Biomed Eng Online, 6 (2007), p. 30, 10.1186/1475-925X-6-30 ↗
Published 2007 Jul 16

View in Scopus ↗ Google Scholar ↗

43 Y. Dong, Y. Chen, B. Yao, *et al.*
Neuropathologic damage induced by radiofrequency ablation at different temperatures
Clinics (Sao Paulo), 77 (2022), Article 100033, 10.1016/j.clinsp.2022.100033 ↗
Published 2022 Apr 15

View PDF View article View in Scopus ↗ Google Scholar ↗

44 N.H. Chua, K.C. Vissers, ME. Sluijter

Pulsed radiofrequency treatment in interventional pain management: mechanisms and potential indications-a review
Acta Neurochir (Wien), 153 (4) (2011), pp. 763-771, 10.1007/s00701-010-0881-5 ↗
View in Scopus ↗ Google Scholar ↗

45 S. Erdine, A. Bilir, E.R. Cosman, Cosman ER Jr
Ultrastructural changes in axons following exposure to pulsed radiofrequency fields
Pain Pract, 9 (6) (2009), pp. 407-417, 10.1111/j.1533-2500.2009.00317.x ↗
View in Scopus ↗ Google Scholar ↗

46 I. Tekin, H. Mirzai, G. Ok, K. Erbuyun, D. Vatansever
A comparison of conventional and pulsed radiofrequency denervation in the treatment of chronic facet joint pain
Clin J Pain, 23 (6) (2007), pp. 524-529, 10.1097/AJP.0b013e318074c99c ↗
View in Scopus ↗ Google Scholar ↗

47 B. Vachirakorntong, E. Kawana, V.P. Zhitny, *et al.*
Radiofrequency Ablation's Effectiveness for Treating Abdominal and Thoracic Chronic Pain Syndromes: A Systematic Review of the Current Literature
Pain Physician, 26 (7) (2023), pp. E737-E759
View in Scopus ↗ Google Scholar ↗

48 AJ. Engel
Utility of intercostal nerve conventional thermal radiofrequency ablations in the injured worker after blunt trauma
Pain Physician, 15 (5) (2012), pp. E711-E718
Crossref ↗ View in Scopus ↗ Google Scholar ↗

49 R. Ramya, N. Loganathan, R.T.C. Kiat, CLM. San
Ultrasound-Guided Radiofrequency Ablation of the Intercostal Nerve for Traumatic Rib Fracture Pain: A Case Report
Pain Med Case Rep, 6 (2) (2022), pp. 61-63
Google Scholar ↗

50 S.M. Cooper, RP. Dawber
The history of cryosurgery
J R Soc Med, 94 (4) (2001), pp. 196-201, 10.1177/014107680109400416 ↗
View in Scopus ↗ Google Scholar ↗

51 SP. Amoils
NITROUS OXIDE AS A COOLANT IN OPHTHALMIC CRYOSURGERY
Arch Ophthalmol, 81 (1) (1969), p. 150, 10.1001/archopht.1969.00990010152029 ↗
View in Scopus ↗ Google Scholar ↗

52 K.M. Nelson, R.G. Vincent, R.S. Bourke, *et al.*
Intraoperative intercostal nerve freezing to prevent postthoracotomy pain
Ann Thorac Surg, 18 (3) (1974), pp. 280-285, 10.1016/s0003-4975(10)64357-3 ↗

View PDF View article View in Scopus ↗ Google Scholar ↗

53 J. Guitron
Histopathologic Study of the Effects of Surgically Applied Cryoanalgesia on Intercostal Nerves in a Live Porcine Model
J Clin Med, 13 (11) (2024), p. 3304, 10.3390/jcm13113304 ↗
Published 2024 Jun 4
View in Scopus ↗ Google Scholar ↗

54 D. Grinsell, CP. Keating
Peripheral nerve reconstruction after injury: a review of clinical and experimental therapies
Biomed Res Int, 2014 (2014), Article 698256, 10.1155/2014/698256 ↗
View in Scopus ↗ Google Scholar ↗

55 R.A. Gabriel, E.C. Seng, B.P. Curran, P. Winston, A.M. Trescot, I. Filipovski
A Narrative Review of Ultrasound-Guided and Landmark-based Percutaneous Cryoneurolysis for the Management of Acute and Chronic Pain
Curr Pain Headache Rep, 28 (11) (2024), pp. 1097-1104, 10.1007/s11916-024-01281-z ↗
View in Scopus ↗ Google Scholar ↗

56 M. Tichenor, L.B. Reparaz, C. Watson, *et al.*
Intrathoracic plates versus extrathoracic plates: a comparison of postoperative pain in surgical stabilization of rib fracture technique
Trauma Surg Acute Care Open, 8 (1) (2023), Article e001201, 10.1136/tsaco-2023-001201 ↗
Published 2023 Nov 3
View in Scopus ↗ Google Scholar ↗

57 S. Stopenski, J. Binkley, S.D. Schubl, ZM. Bauman
Rib fracture management: A review of surgical stabilization, regional analgesia, and intercostal nerve cryoablation
Surg Pract Sci, 10 (2022), Article 100089, 10.1016/j.sipas.2022.100089 ↗
Published 2022 May 16
View PDF View article View in Scopus ↗ Google Scholar ↗

58 M.N. Marturano, V. Thakkar, H. Wang, *et al.*
Intercostal nerve cryoablation during surgical stabilization of rib fractures decreases post-operative opioid use, ventilation days, and intensive care days
Injury, 54 (9) (2023), Article 110803, 10.1016/j.injury.2023.05.034 ↗
View PDF View article View in Scopus ↗ Google Scholar ↗

59 C.A. Fernandez, J.R. Narveson, F. Niu, *et al.*
In-hospital outcomes of intercostal nerve cryoablation and surgical stabilization of rib fractures
J Trauma Acute Care Surg, 93 (5) (2022), pp. 695-701, 10.1097/TA.0000000000003623 ↗
View in Scopus ↗ Google Scholar ↗

60 M. Tichenor, L.B. Reparaz, C. Watson, *et al.*

Intrathoracic plates versus extrathoracic plates: a comparison of postoperative pain in surgical stabilization of rib fracture technique
Trauma Surg Acute Care Open, 8 (1) (2023), Article e001201, 10.1136/tsaco-2023-001201 ↗
Published 2023 Nov 3
View in Scopus ↗ Google Scholar ↗

61 Iv JJ Finneran, R.A. Gabriel, M.W. Swisher, *et al.*
Ultrasound-guided percutaneous intercostal nerve cryoneurolysis for analgesia following traumatic rib fracture -a case series
Korean J Anesthesiol, 73 (5) (2020), pp. 455-459, 10.4097/kja.19395 ↗
View in Scopus ↗ Google Scholar ↗

62 C.I. Villalta, R.K. Mian, H.M. Grossman Verner, *et al.*
Bedside percutaneous cryoneurolysis technique for management of acute rib fracture pain in adult trauma patients
Trauma Surg Acute Care Open, 9 (1) (2024), Article e001521, 10.1136/tsaco-2024-001521 ↗
Published 2024 Aug 22
View in Scopus ↗ Google Scholar ↗

63 P.I. Cha, J.G. Min, A. Patil, J. Choi, N.N. Kothary, JD. Forrester
Efficacy of intercostal cryoneurolysis as an analgesic adjunct for chest wall pain after surgery or trauma: systematic review
Trauma Surg Acute Care Open, 6 (1) (2021), Article e000690, 10.1136/tsaco-2021-000690 ↗
Published 2021 May 18
View in Scopus ↗ Google Scholar ↗

64 H. Ju, Y. Feng, B.X. Yang, J. Wang
Comparison of epidural analgesia and intercostal nerve cryoanalgesia for post-thoracotomy pain control
Eur J Pain, 12 (3) (2008), pp. 378-384, 10.1016/j.ejpain.2007.07.011 ↗
View PDF View article View in Scopus ↗ Google Scholar ↗

65 S. Majercik, Q. Cannon, S.R. Granger, D.H. VanBoerum, TW. White
Long-term patient outcomes after surgical stabilization of rib fractures
Am J Surg, 208 (1) (2014), pp. 88-92, 10.1016/j.amjsurg.2013.08.051 ↗
View PDF View article View in Scopus ↗ Google Scholar ↗

66 J. Choi, S. Khan, D. Sheira, N.A. Hakes, L. Aboukhater, DA. Spain
Prospective study of long-term quality-of-life after rib fractures
Surgery, 172 (1) (2022), pp. 404-409, 10.1016/j.surg.2021.11.026 ↗
View PDF View article View in Scopus ↗ Google Scholar ↗

67 M.K. Karmakar, AM. Ho
Postthoracotomy pain syndrome
Thorac Surg Clin, 14 (3) (2004), pp. 345-352, 10.1016/S1547-4127(04)00022-2 ↗
View PDF View article View in Scopus ↗ Google Scholar ↗

68 A. Abd-Elsayed, S. Lee, M. Jackson
Radiofrequency Ablation for Treating Resistant Intercostal Neuralgia
Ochsner J, 18 (1) (2018), pp. 91-93
View in Scopus ↗ Google Scholar ↗

69 E.H. Williams, C.G. Williams, G.D. Rosson, R.F. Heitmiller, AL. Dellon
Neurectomy for treatment of intercostal neuralgia
Ann Thorac Surg, 85 (5) (2008), pp. 1766-1770, 10.1016/j.athoracsur.2007.11.058 ↗
View PDF View article View in Scopus ↗ Google Scholar ↗

70 R. Melzack, PD. Wall
Pain mechanisms: a new theory
Science, 150 (3699) (1965), pp. 971-979, 10.1126/science.150.3699.971 ↗
View in Scopus ↗ Google Scholar ↗

71 Christopher Morris, K. Vorenkamp, J. Ward
PNS for management of intercostal neuralgia: A case report
Interv Pain Med, 4 (1) (2025), Article 100573, 10.1016/j.inpm.2025.100573 ↗
Published 2025 Mar 18
Google Scholar ↗

72 D.M. Gallacher, P. Gastelum, SA. Park
Intercostal Neuralgia Successfully Managed With Peripheral Nerve Stimulation
Cureus, 16 (10) (2024), Article e71964, 10.7759/cureus.71964 ↗
Published 2024 Oct 20
Google Scholar ↗

73 N. Strand, R.S. D'Souza, J.M. Hagedorn, *et al.*
Evidence-Based Clinical Guidelines from the American Society of Pain and Neuroscience for the Use of Implantable Peripheral Nerve Stimulation in the Treatment of Chronic Pain
J Pain Res, 15 (2022), pp. 2483-2504, 10.2147/JPR.S362204 ↗
Published 2022 Aug 23
View in Scopus ↗ Google Scholar ↗

Cited by (0)

Dr. Zachary Bauman is a paid educational consultant for KLS-Martin, Zimmer-Biomet and Atricure, and Smith&Nephew. All authors agree to publication of this article in its current form. No funding for this project.

© 2026 The Authors. Published by Elsevier Inc.

ELSEVIER

All content on this site: Copyright © 2026 Elsevier B.V., its licensors, and contributors. All rights are reserved, including those for text and data mining, AI training, and similar technologies.
For all open access content, the relevant licensing terms apply.

RELX™